

See discussions, stats, and author profiles for this publication at: <https://www.researchgate.net/publication/292629160>

A New Approach to ACL Anatomy.

Article · December 2015

CITATIONS

0

READS

2,427

2 authors:



Robert Smigielski

Medical University of Warsaw

66 PUBLICATIONS 732 CITATIONS

[SEE PROFILE](#)



Urszula Zdanowicz

Carolina Medical Center

38 PUBLICATIONS 394 CITATIONS

[SEE PROFILE](#)

Some of the authors of this publication are also working on these related projects:



Novel Scaffold-based Tissue Engineering Approaches to Healing and Regeneration of Tendons and Ligaments (START) [View project](#)



Phantom unloader [View project](#)

A NEW APPROACH TO ACL ANATOMY

THE RIBBON CONCEPT

– Written by Robert Smigielski and Urszula Zdanowicz, Poland

Anterior cruciate ligament (ACL) injury is one of the most common knee injuries, with an estimated incidence of 1 in 3000 in the USA¹. Chronic ACL deficiency is associated with a high incidence of early osteoarthritis (OA). Thus it would be logical to assume that if reconstructive surgery restores knee stability, it should reduce the risk of subsequent OA². Unfortunately an increasing number of studies show that the risk of early OA is similar or even sometimes higher after ACL reconstruction, compared to those ACL-deficient patients who were treated non-operatively^{2,3}. Tashman et al² showed that although restoration of normal anterior/posterior motion patterns is possible with current ACL reconstruction techniques, it does not necessarily imply normal knee function. That is probably why there is a growing interest in an anatomical approach to ACL reconstruction techniques.

Many researchers believe this might be key to improving long-term results and reducing the risk of early OA. Therefore a comprehensive and detailed understanding of ACL anatomy has become more important than ever.

Seneca said: “Omnis ars naturae imitatio est”, which could be translated as “All art is nothing but imitation of nature”.

During the last few years there have been two dominating theories on ACL anatomy: the double-bundle concept and, since 2012, the ribbon-concept of ACL anatomy (first presented in ‘The Ribbon Concept of the Anterior Cruciate Ligament’ by R. Smigielski, at the ACL Study Group Meeting, 2012 in Jackson Hole, Wyoming, USA).

This article will present the key points of ribbon-like ACL anatomy theory.

FLAT, RIBBON-LIKE AND TWISTING ACL

In their anatomical study⁴, Smigielski et al dissected 111 fresh frozen cadaveric knees. All osteoarthritic specimens (grade IV chondromalacia) were excluded from the study. The mean age was 67 (range 32 to 74 years old), with 66 female and 45 male subjects. In all dissected knees, the ACL formed a flat, ribbon-like ligament (Figure 1). Its average width (at the level of 2 mm from femoral insertion) was 16 mm, while the mean thickness was 3.54 mm. The authors could not differentiate two bundles within the ACL (Figure 2), which supported the findings of previous studies by Arnoczky and Welsh^{5,6}. However, looking closely at the ACL mid-substance and the way it changes its position during knee flexion-extension, one may notice a ‘double bundle effect’, created by the twisted flat ribbon-like structure. With different knee flexion angles, different groups of ACL fibres become tight


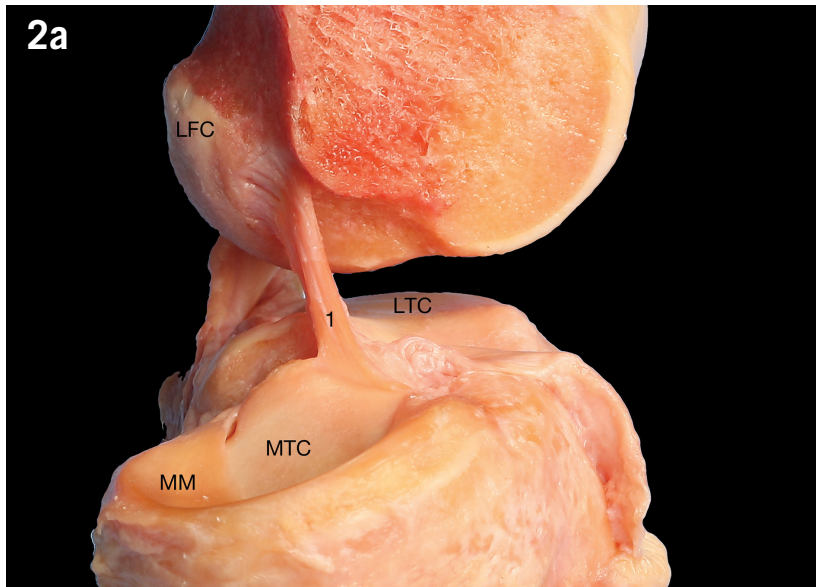
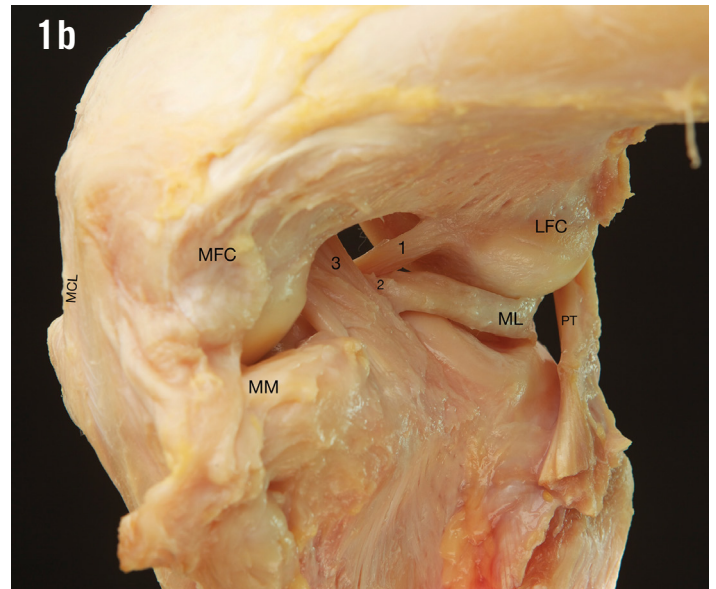
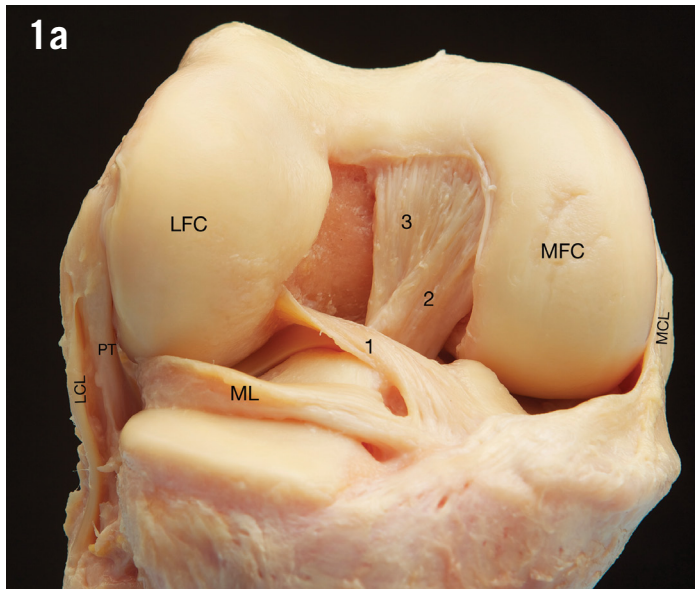


Figure 1: (a) Cadaveric dissection of right knee joint, patella is removed, view from the front. LFC=lateral femoral condyle, MFC=medial femoral condyle, ML=lateral meniscus, MCL=medial collateral ligament, LCL=lateral collateral ligament, PT=popliteus tendon, 1=anterior cruciate ligament, 2=anterior menisco-femoral ligament (Humphrey ligament), 3=posterior cruciate ligament. Notice: flat, ribbon-like appearance of ACL, very low femoral attachment, reaching to articular surface of lateral femoral condyle. (b) View from postero-medial side.

Figure 2: (a) Cadaveric dissection of the left knee joint, medial femoral condyle is removed. MM=medial meniscus, LFC=lateral femoral condyle, MTC=medial tibial condyle, LTC=lateral tibial condyle, 1=anterior cruciate ligament. (b) ACL cut off. Notice flat, ribbon-like structure.

or loose. With the knee in full extension, the ACL lies vertically (in the sagittal plane), (Figure 2a) and with knee flexion the ACL lies more horizontally (Figure 1a). Given this phenomenon, even a narrow intercondylar notch can easily accommodate a wide, flat ACL. Therefore, there is no reason why notch-plasty would be required in the natural setting, yet it is required for some reconstructive techniques. One can find similar observations in the literature as far back as 1975, Girgis⁷.

In 1998 Amis et al⁸ also described the twisting nature of the ACL when the

ligament is viewed from the front, with the knee flexed, as it is during knee arthroscopy. This twist unwinds as the knee extends. If during ACL reconstruction, the femoral attachment of the graft is fixed first, one should externally rotate the graft to mimic the anatomical fibre arrangement. Experiments in vitro have suggested that a 90° twist stiffens the construct and provides a higher failure load. The other advantage of twisting the graft to mimic the native ACL, is that it increases the options for graft choice, as wide as you believe it needs to be without incurring a risk of impingement.

FEMORAL ATTACHMENT

The ACL femoral attachment is a semilunar shape⁴, (Figure 3a and b). It extends posteriorly and superiorly to the articular cartilage margin⁹ (Figure 3c).

The ACL midsubstance arises from the resident's ridge. The resident's ridge is a thick ridge in the medial wall of the lateral femoral condyle that runs the length of the ACL insertion from anterior to posterior¹⁰. This ridge, (as well as the ACL insertion) is in line with the posterior femoral cortex^{4,11,12}, (Figure 4), and is an excellent bony landmark, easily identified during both

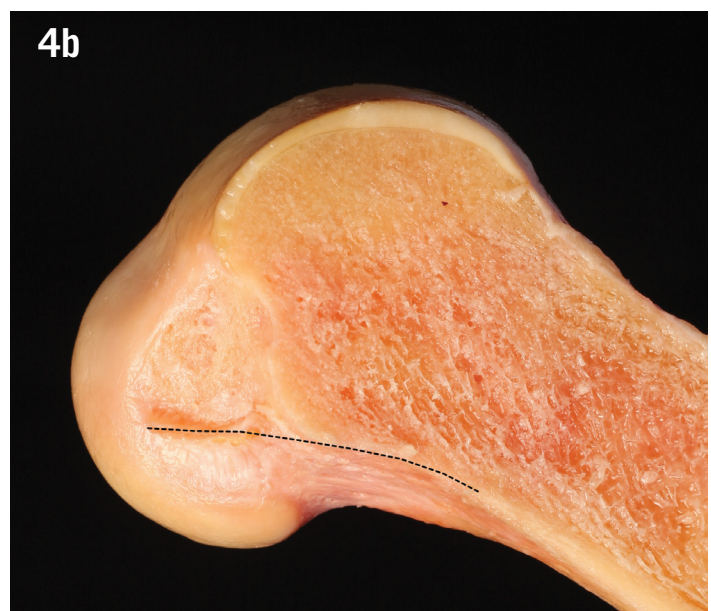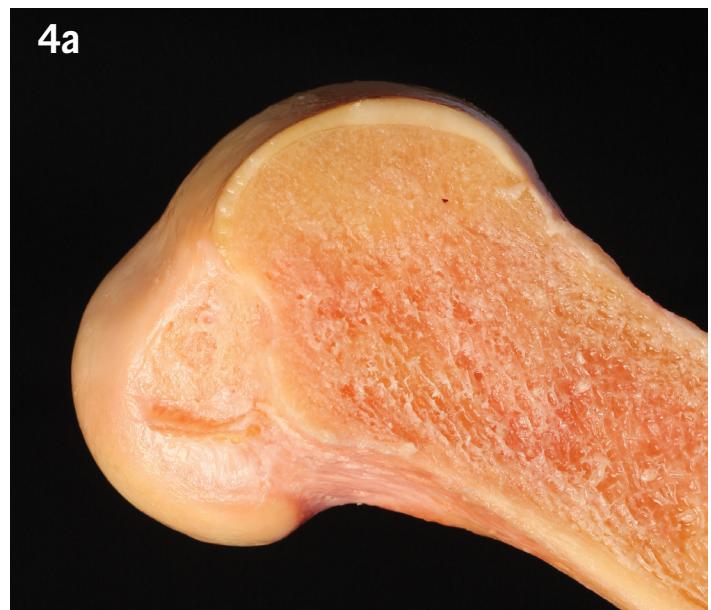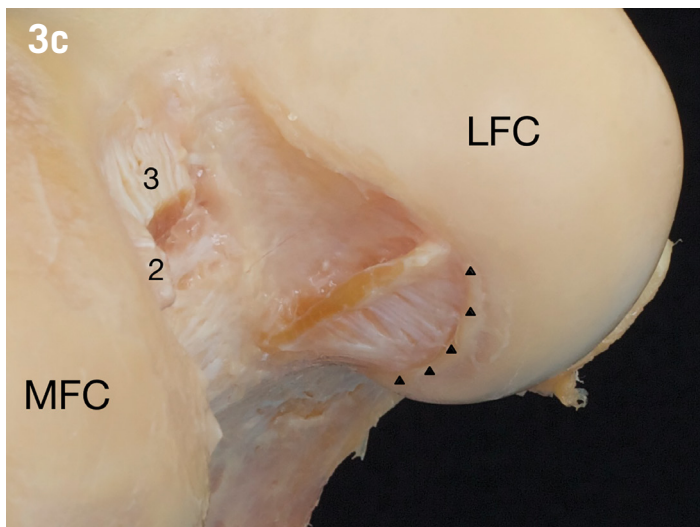
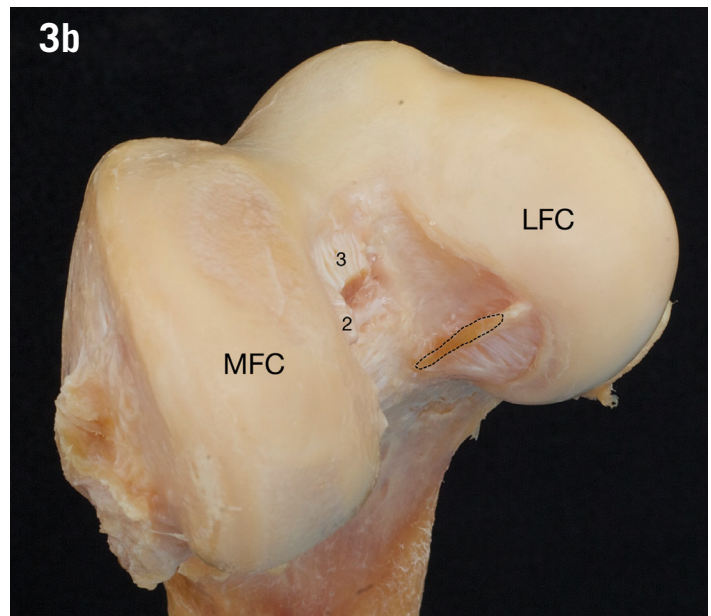
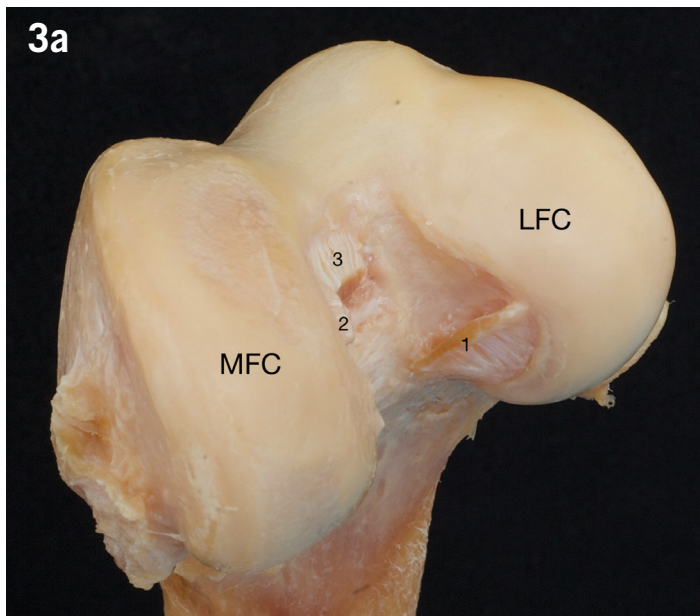


Figure 3: Cadaveric dissection of the left knee joint, distal femur, antero-inferior view. (a) MFC=medial femoral condyle, LFC=lateral femoral condyle, 1=anterior cruciate ligament, 2=femoral attachment of anterior menisco-femoral ligament (Humphrey ligament), 3=femoral attachment of posterior cruciate ligament. (b) Same view. Flat structure of ACL is marked with black, dotted line. (c) Close look at the femoral ACL attachment. Notice flat, ribbon-like structure of ACL midsubstance and the way femoral ACL attachment reaches the articular surface border of lateral femoral condyle – marked with arrowheads.

Figure 4: (a) Cadaveric dissection of the right lateral femoral condyle. Notice the femoral insertion of ribbon-like ACL fibres are in line with posterior femoral cortex (marked with black dotted line (b)).

knee arthroscopy and C-arm X-ray. This allows for double-checking of the correct position of tunnel placement during ACL reconstruction.

However, correct tunnel placement depends on the choice of graft and fixation technique. For example with hamstring tendon graft and endo-button fixation, the center of the tunnel should be the centre of the insertion. However for the same graft, but with interference screw fixation – which allows for the graft to move to the side – a different tunnel placement is required, because the graft will arise from the side of the tunnel. When choosing tunnel

placement, one must always consider the following three elements, which heavily influence the final decision before drilling: the ACL stump (if available), the type of graft and the type of fixation technique.

The femoral ACL insertion consists of two different structures: the direct and indirect fibres⁹. Direct insertion has a zonal architecture. This means that between the ligament and the bone there is a layer of fibrocartilage. According to Schneider¹³ that flexible pad of fibrocartilage acts as a ‘two layer defense system’ that protects the bone against excessive shearing stress. The indirect insertion has a simpler structure,

where the ligament attaches to the bone with no, or almost no transitional zone. Schneider even argued that the structure of the attachment zone varies in a given tendon according to the occupation of the person. Noncalcified fibrocartilage plays a role in bending control that occurs while the ligament changes direction. Whereas the indirect insertion plays a role as a dynamic anchorage of soft tissue to the bone, allowing certain shear movement. The strength of anchoring is weaker than the direct insertion. Therefore it would be ideal to make the femoral tunnel on the direct insertion in native ACL^{10,14,15}.

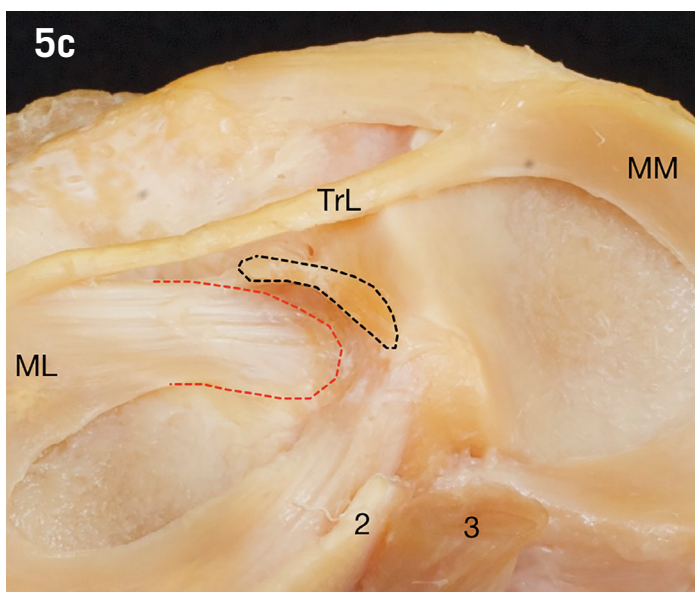
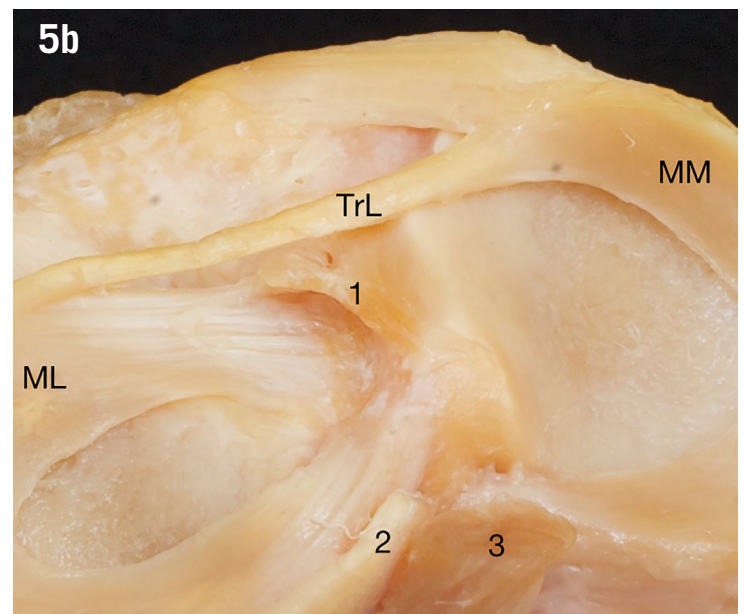
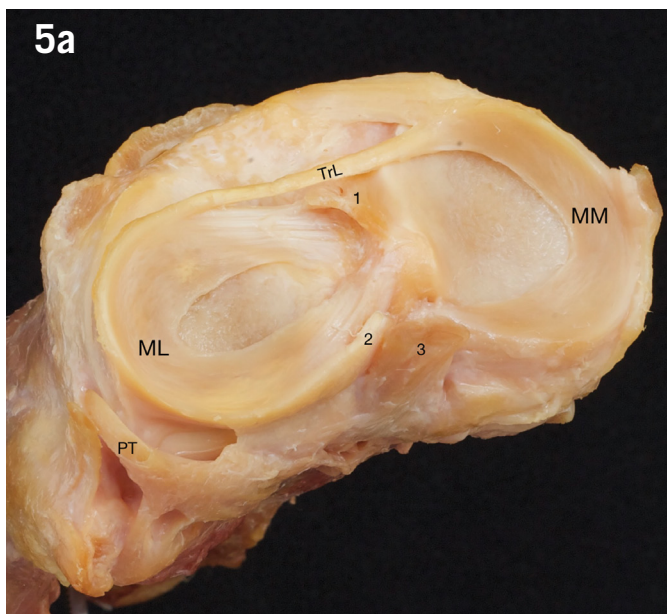


Figure 5: (a) Cadaveric dissection of the left knee joint. MM=medial meniscus, ML=lateral meniscus, PT=popliteus tendon, TrL=transverse ligament, 1=anterior cruciate ligament, 2=anterior menisco-femoral ligament (Humphrey ligament), 3=posterior cruciate ligament. (b) Closer look on the same specimen. (c) The relationship between anterior horn of lateral meniscus (red dashed line) and tibial attachment of ACL (black dashed line). Notice how ACL attachment surrounds lateral meniscus.

TIBIAL ATTACHMENT

The tibial attachment of the ACL is 'C'-shaped¹⁶ (Figure 5). The centre of the 'C' is the bony attachment of the anterior root of the lateral meniscus. The ACL surrounds and covers the anterior root of the lateral meniscus. This is the crucial difference between 'double-bundle' and 'ribbon-like' theories of ACL anatomy.

The double-bundle theory states there is an antero-medial and postero-lateral bundle¹⁷. The tibial attachment site of the postero-lateral bundle projects down to the area where, according to Smigielski and Siebold¹⁸ the anterior root of the lateral meniscus attaches. The posterior ACL fibres of the 'C' insert medially along the medial tibial spine. In ribbon theory, within the tibial attachment there would rather be an antero-medial and postero-medial part, as proposed by Siebold.

Additionally Smigielski et al described three different types of tibial ACL attachment. The most frequent type (constituting 67% of knees) is a 'C' type. The 'J' type is usually positioned in the sagittal plane and constitutes 24% of cases. And finally the 'Cc' type represents 9%¹⁸.

CONSEQUENCES FOR ACL RECONSTRUCTION

The primary benefit of ribbon-like theory is that you may achieve the postulated flat shape of an ACL graft – as well as the shape of femoral and tibial attachment – in many different ways, with many different grafts, according to preference and availability. All the following graft types could potentially work:

- flat patellar tendon graft with bone blocks,
- rectus femoris tendon or
- hamstring tendons.

The interference screw is probably the easiest fixation to use to reproduce the twisting nature of the graft or to move it aside to create the flat line arrangement within the femoral attachment or 'C' shaped tibial attachment.

Acknowledgements

The authors gratefully acknowledge Maciej Smiarowski (maciej.smiarowski@gmail.com) for taking photographs and Center for Medical Education (www.cemed.pl) for its help.

References

1. Davarinos N, O'Neill BJ, Curtin W. A brief history of anterior cruciate ligament reconstruction. *Advances in Orthopedic Surgery* 2014; 2014:1-6.
2. Tashman S, Collon D, Anderson K, Kolowich P, Anderst W. Abnormal rotational knee motion during running after anterior cruciate ligament reconstruction. *Am J Sports Med* 2004; 32:975-983.
3. Fink C, Hoser C, Benedetto KP. [Development of arthrosis after rupture of the anterior cruciate ligament. A comparison of surgical and conservative therapy]. *Unfallchirurg* 1994; 97:357-361.
4. Smigielski R, Zdanowicz U, Drwiega M, Cizek B, Ciszowska-Lyson B, Siebold R. Ribbon like appearance of the midsubstance fibres of the anterior cruciate ligament close to its femoral insertion site: a cadaveric study including 111 knees. *Knee Surg Sports Traumatol Arthrosc* 2015; 23:3143-3150.
5. Arnoczky SP. Anatomy of the anterior cruciate ligament. *Clin Orthop Relat Res* 1983; 19-25.
6. Welsh RP. Knee joint structure and function. *Clin Orthop Relat Res* 1980; 7-14.
7. Girgis FG, Marshall JL, Monajem A. The cruciate ligaments of the knee joint. Anatomical, functional and experimental analysis. *Clin Orthop Relat Res* 1975; 216-231.
8. Amis AA, Jakob RP. Anterior cruciate ligament graft positioning, tensioning and twisting. *Knee Surg Sports Traumatol Arthrosc* 1998; 6:S2-S12.
9. Iwahashi T, Shino K, Nakata K, Otsubo H, Suzuki T, Amano H, Nakamura N. Direct anterior cruciate ligament insertion to the femur assessed by histology and 3-dimensional volume-rendered computed tomography. *Arthroscopy* 2010; 26:S13-20.
10. Sasaki N, Ishibashi Y, Tsuda E, Yamamoto Y, Maeda S, Mizukami H, et al. The femoral insertion of the anterior cruciate ligament: discrepancy between macroscopic and histological observations. *Arthroscopy* 2012; 28:1135-1146.
11. Tsukada H, Ishibashi Y, Tsuda E, Fukuda A, Toh S. Anatomical analysis of the anterior cruciate ligament femoral and tibial footprints. *J Orthop Sci* 2008; 13:122-129.
12. Hara K, Mochizuki T, Sekiya I, Yamaguchi K, Akita K, Muneta T. Anatomy of normal human anterior cruciate ligament attachments evaluated by divided small bundles. *Am J Sports Med* 2009; 37:2386-2391.
13. Schneider H. [Structure of tendon attachments]. *Z Anat Entwicklungsgesch* 1956; 119:431-456.
14. Kumai T, Takakura Y, Rufai A, Milz S, Benjamin M. The functional anatomy of the human anterior talofibular ligament in relation to ankle sprains. *J Anat* 2002; 200:457-465.
15. Evans EJ, Benjamin M, Pemberton DJ. Fibrocartilage in the attachment zones of the quadriceps tendon and patellar ligament of man. *J Anat* 1990; 171:155-162.
16. Siebold R, Schuhmacher P, Fernandez F, Smigielski R, Fink C, Brehmer A et al. Flat midsubstance of the anterior cruciate ligament with tibial "C"-shaped insertion site. *Knee Surg Sports Traumatol Arthrosc* 2015; 23:3136-3142.
17. Siebold R, Ellert T, Metz S, Metz J. Tibial insertions of the anteromedial and posterolateral bundles of the anterior cruciate ligament: morphometry, arthroscopic landmarks, and orientation model for bone tunnel placement. *Arthroscopy* 2008; 24:154-161.
18. Siebold R, Dejour D, Zaffagnini S. Anterior cruciate ligament reconstruction: a practical surgical guide; 2014.

Robert Smigielski M.D.

Head of Orthopaedic and Sports Traumatology Department

Urszula Zdanowicz M.D.

Orthopaedic Surgeon
Orthopaedic and Sports Traumatology Department

Carolina Medical Center

Warsaw, Poland

Contact: robert.smigielski@carolina.pl